

Assessment of a Quick Monofilament Suture in Paediatric Urology - A Prospective, Single Centre, Observational Cohort Study

Petra Baumann^{1,*}, Stefan Gfroerer^{2,3}

¹Department of Medical Scientific Affairs, Aesculap, Tuttlingen, Germany

²Department of Paediatric Surgery and Paediatric Urology, University Hospital Frankfurt, Frankfurt am Main, Germany

³Department of Paediatric Surgery, Helios Clinic, Berlin-Buch, Berlin, Germany

E-mail address:

petra.baumann@aesculap.de (Petra Baumann), stefan.gfroerer@helios-gesundheit.de (Stefan Gfroerer)

*Corresponding author

To cite this article:

Petra Baumann, Stefan Gfroerer. Assessment of a Quick Monofilament Suture in Paediatric Urology - A Prospective, Single Centre, Observational Cohort Study. *Journal of Surgery*. Vol. 11, No. 6, 2023, pp. 124-131. doi: 10.11648/j.js.20231106.11

Received: August 16, 2023; **Accepted:** October 12, 2023; **Published:** November 9, 2023

Abstract: Absorbable sutures of different filament structure and absorption profile are commonly used for the repair of paediatric urological pathologies. Review of the literature shows that there is no consensus about the optimal suture technique and the ideal suture material. The selected type of the suture material (either monofilament or braided and either fast absorbable or long-term absorbable) as well as the suture technique (continuous or interrupted) are mainly based on the surgeon's preference. The present prospective observational study assessed, for the first time, the clinical performance of a new quick-absorbable monofilament suture (Monosyn[®] Quick) made from a triblock copolymer in paediatric urology and compares the clinical outcome to the available literature data. A total of 53 children were enrolled. The intraoperative handling of the sutures was judged by the paediatric surgeons using a 5-point Likert scale (1: poor to 5: excellent). The handling parameters were knot security, tensile strength, pliability and tissue drag. The outcomes of the wound healings were rated by the patients/parents and observers (surgeons) using the Patient and Observer Scar Assessment Scale (POSAS) at 3 months \pm 10 days after surgery. The resulting hospital stay was short with an average of 1.32 ± 1.27 days. Neither wound healing complications nor other adverse events occurred until 3 months after surgery. The mean POSAS value was 11.56 ± 5.84 for the Patient component and 12.52 ± 6.51 for the Observer component, indicating an excellent aesthetic result. All suture handling dimensions were mostly rated with 4 to 5 points revealing a comfortable and safe handling. In conclusion, this is the first study which prospectively evaluates the handling and clinical outcomes of a quick absorbable, monofilament suture in paediatric urological repairs. Results indicate that the investigated suture represents a viable suture for paediatric urological surgeries.

Keywords: Urology, Paediatrics, Quick-Absorbable, Monofilament, Suture, Surgery, Hypospadias, Orchidopexy

1. Introduction

There are numerous urological pathologies in childhood i.e. phimosis, undescended testis, dilatation of the upper urinary tract (UUT) due to an obstruction of the ureteropelvic junction (UPJ) or the ureterovesical junction (UVJ), hypospadias and others. Genitourinary diseases need appropriate treatment, often surgical. They frequently have an impact on long-term quality of life. Focusing on non-oncological diseases, apart from the merely functional outcomes, genitourinary diseases

have been related with adult male's mental health and negative self-perception, even after corrective surgery [1, 2].

It is crucial that the surgical procedure is performed under optimal conditions. The suture material plays an important part and should be characterized by easy handling, avoidance of local reactions, and sufficient tensile for tissue adaptation in order to facilitate the best possible aesthetic result. Traditionally, quick-absorbable, braided sutures have been used for skin closure in adults and children [3]. Epidermal closure with absorbable sutures has the benefit that a suture removal is not necessary, which is a certain advantage

especially in paediatric patients. The European Association of Urology includes absorbable sutures as a common practice in the surgical correction of certain pathologies such as phimosis and hypospadias [4] and their use has been linked to a lower incidence of complications compared to non-absorbable sutures for certain pathologies [5].

While there is a general agreement on the use of absorbable sutures, the type of the suture technique (continuous or interrupted) as well as the filament structure (monofilament or multifilament braided) and the absorption profile (short-term or long-term absorbable) of the suture material remains debated. The choice of the suture technique and type of the suture material is predominantly dictated by the surgeon's preference.

Sarhan et al. were the first who analysed the influence of the suture technique (continuous subcuticular versus interrupted subcuticular) on the complication rate following hypospadias repair by using the Thiersch-Duplay technique (TIP) in a randomised controlled trial [6]. The incidence of postoperative complications after hypospadias repair is 1-24% [7]. Urethrocutaneous fistula and meatal stenosis are common complications occurring after hypospadias repair and recent studies reported rates up to 16% and 9%, respectively [6, 8]. Sarhan et al. reported an overall complication rate of 13.5%, which consisted of fistula (10%), meatal stenosis (3.75%) and dehiscence (2.5%). They concluded that the suture technique had no influence on the outcome of the TIP urethroplasty, because the overall complication rate was comparable between the continuous and the interrupted suture group (12.5% vs. 15%, respectively). These findings were confirmed by another randomised study performed in 2019 by Gupta et al. who compared the interrupted and continuous suture urethroplasty in tubularised incised plate hypospadias repair. [9]. Similar complication rates were found with respect to urethrocutaneous fistula, wound dehiscence, wound infection and meatal stenosis in both suture technique groups.

Previously performed RCT concluded that the success rate of hypospadias repair is mostly influenced by patient age, hypospadias type, urethral plate width, type of repair and the experience of the procedure applied [6, 8, 10]. Whereas the type of suture technique seems to have no influence on the occurrence of complications, however, due to the small sample size of the studies it was mentioned that larger studies are required to support this conclusion.

The review of the literature showed no consensus about the optimal suture type. Several studies have compared the clinical outcome of braided fast absorbable suture versus monofilament mid-term or long-term absorbable sutures for hypospadias repair [10-15]. The comparison of braided fast absorbable polyglactin sutures with monofilament long-term absorbable polydioxanone sutures showed that complications were more prevalent in the polyglactin group, especially with regard to a urethrocutaneous fistula. Therefore, the authors favoured the use of a monofilament long-term absorbable suture because it is associated with a lower complication rate [10, 11, 13-15]. Guarino et al. analysed the result of hypospadias repair using either a fast absorbable

monofilament polyglytone suture or a long-term absorbable monofilament polydioxanone suture [12]. No significant difference could be seen in terms of urethral fistula, dehiscence and infection. Both sutures were assessed as suitable for hypospadias repair in small children, but the use of a polyglytone suture seems to be beneficial because of its faster absorption time combined with an adequate tensile strength [12].

A new fast-absorbable monofilament suture made from a triblock copolymer comprising glycolide (72%), ϵ -caprolactone (14%) and trimethylene carbonate (14%) named Monosyn® Quick was released in 2016. This suture material loses 50% of its tensile strength 7 days after implantation. The tensile strength is completely lost after 14-21 days and the suture material is fully absorbed after 56 days post implantation.

The present study was designed to systematically assess for the first time the clinical performance of a new quick-absorbable, monofilament suture (Monosyn® Quick) in several paediatric urological surgeries under daily clinical practice and to compare the outcome with available literature data.

2. Methods

2.1. Study Design: Participants and Ethical Consideration

The study design was a prospective, monocentric, single-arm, observational cohort study to systematically analyse the clinical performance of Monosyn® Quick sutures in paediatric urological procedures. Enrollment took place between September 2018 and May 2019 at a university hospital in Germany. The patients were recruited from the patient population treated at the participating clinic as part of daily clinical routine according to the hospital's standard. The first child was enrolled on 5 September 2018. The 3-month follow-up of the study population was completed on 4 September 2019. The participating patients were examined on the day of discharge and 3 months after surgery. No additional follow-up visits were performed for this observational study.

Inclusion criteria were paediatric patients undergoing urological intervention (e.g. circumcision, orchidopexy, hypospadias repair) under the use of Monosyn® Quick sutures. No exclusion criteria were selected. The suture material was Monosyn® Quick manufactured by B. Braun Surgical S. A., Rubi, Spain. The interrupted transcutaneous or the continuous intracutaneous suture technique was chosen for epidermal closure. The suture material was used according to the instruction of use. Regular monitoring visits were performed at the hospital to ensure the quality and validity of the data. Data collection was performed in a paper-based Case Report Form (CRF) and transferred by data management to an online database owned by the study sponsor.

The study was conducted according to the Declaration of Helsinki and registered in clinicaltrials.gov (28 Nov. 2017) before start of recruitment [NCT03355001]. The ethics committee of the University Hospital Frankfurt, Germany,

endorsed the study design prior to patient acquisition (ref. no. 101/18 on 9 July 2018). Before inclusion in the study, a written informed consent was obtained from the patients and/or parents. Included were only paediatric patients under the age of 18. The present study is reported online with the STROCCS Guideline, which is a standard for the publication of cohort studies [16].

2.2. Outcomes

The handling properties of the sutures were assessed by the surgeons during the skin adaptation. Performance was documented by using a 5-point Likert scale (5: excellent, 4: very good, 3: good, 2: satisfactory, 1: poor) after each urological intervention. The following handling categories were judged: knot security, tensile strength, pliability and tissue drag. Thread rupture, knots in the thread, a bent thread and a defect in needle-thread attachment were classified as suture-related complications.

Efficacy was evaluated based on the evaluation of the aesthetic wound healing result 3 months postoperatively using the Patient Observer Scar Assessment-Scale (POSAS). POSAS is an internationally validated and reliable measure for the assessment of scar quality [17]. The surgeon used the Observer component of the POSAS to assess the cosmetic outcome of the wound. The Observer component of the POSAS scale evaluates 6 different dimensions, each one having a 10-level rating scale (from 1 [normal skin] to 10 [worst scar imaginable]) and consists of the following criteria: 1) vascularity (presence of vessels in the scar tissue assessed by the amount of redness tested by the amount of blood return after blanching with a piece of plexiglass; 2) pigmentation (brownish coloration of the scar by pigmentation; apply transparent plexiglass to the skin with moderate pressure to eliminate the effect of vascularity; 3) thickness (average distance between the subcuticular-dermal border and the epidermal surface of the scar; 4) relief (the extent to which surface irregularities are present, preferably compared with adjacent normal skin); 5) pliability (suppleness of the scar tested by wrinkling the scar between the thumb and index finger); 6) surface area (surface area of the scar in relation to the original wound area). The Patient component of POSAS includes six questions which had to be answered using a 10-point Likert scale (1: like normal to 10: very different from normal skin). In the present study, the assessment was mainly made by the parents because most patients were too young to evaluate on their own. The POSAS score ranges from a minimum of 6 points to a maximum of 60 points for each component.

The safety evaluation of the suture material was achieved by analysing the incidences of wound dehiscence, surgical site infection, tissue reaction, allergic reaction, seroma formation, fistula or abscess formation and haematoma as well as the need for thread removal due to incomplete or non-absorption of the suture until 3 months after surgery. In addition, the length of hospital stay was reported.

2.3. Statistical Methods and Sample Size

All paediatric patients who underwent urological surgery with Monosyn[®] Quick for skin closure without any protocol violation were included in the per-protocol analysis. A sample size calculation was not performed. The sample size was determined based on the number of patients, which could be enrolled in a small monocentric study within a reasonable time period. We hypothesized that a population of 50 paediatric patients would be large enough for evaluation. The outcome of this cohort study was descriptively analysed. SAS software version 9.4 (SAS Institute Inc. Cary, NC, USA) was used for statistical analysis. Missing data were not replaced by estimates, but analysed as such. Variables with metric or ordinal scale were summarised with number of patients (N), minimum (Min.), maximum (Max.), median, mean and standard deviation (SD). Categorical variables were summarised by category to absolute (N) and relative (%) frequency, with missing values having their own category.

3. Results

3.1. Recruitment and Follow-up Examination

The cohort included 53 consecutive patients. Monosyn[®] Quick sutures were applied in all cases for skin closure in various urological repairs. One case was lost to FU 3 months after surgery (Figure 1).

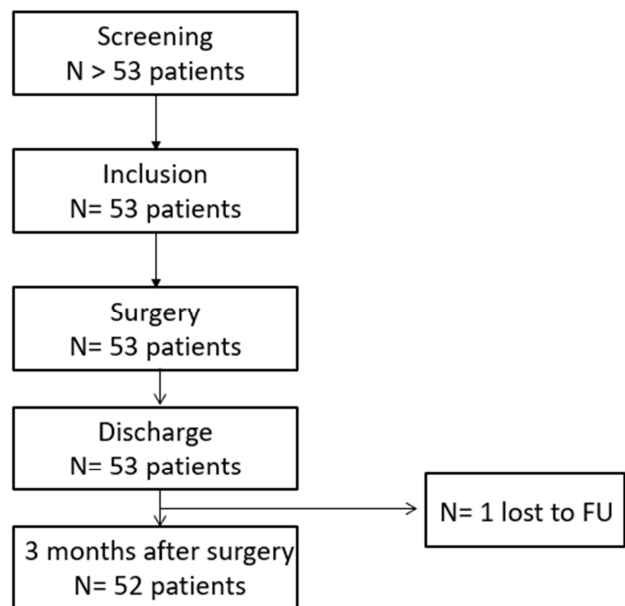


Figure 1. Flow chart of the study.

3.2. Demographics and Baseline Characteristics

The paediatric population comprised 18 infants (≤ 1 years), 30 children and toddlers (age >1 -11 years) and five adolescents (12-18 years). The demographic data of the subgroups are shown in Table 1.

Table 1. Demographic data of the study cohort.

Parameter	Subgroup	Number (N)	Median (Range min. - max.)	Mean (SD)
Age (years)	All	53	2.25 (0.33 – 16.58)	4.29 (4.52)
	Infant	18	0.83 (0.33 – 1.00)	0.81 (0.15)
	Child	30	3.00 (1.08 – 11.83)	4.72 (3.38)
	Adolescent	5	14.08 (12.25 – 16.58)	14.22 (1.94)
	All	53	13.00 (6.00 – 78.00)	19.48 (16.13)
Weight (kg)	Infant	18	9.00 (6.00 – 11.00)	8.71 (1.35)
	Child	30	15.50 (7.60 – 50.00)	20.01 (11.45)
	Adolescent	5	52.00 (30.00 – 78.00)	55.00 (17.94)
	All	53	89.00 (62.00 – 180.00)	100.74 (32.54)
Height (cm)	Infant	18	74.00 (62.00 – 80.00)	72.78 (5.26)
	Child	30	97.50 (76.00 – 162.00)	106.80 (25.05)
	Adolescent	5	162.00 (152.00–180.00)	165.00 (12.08)
	All	53	16.62 (11.63 – 25.47)	16.72 (2.78)
BMI (kg/m ²)	Infant	18	16.44 (11.98 – 20.09)	16.45 (1.95)
	Child	30	16.53 (11.63 – 21.37)	16.36 (2.54)
	Adolescent	5	20.06 (12.33 – 25.47)	19.88 (4.90)

3.3. Intraoperative Details

The main indication for surgery was orchidopexy followed by hypospadias repair, Table 2. The mean operative time for all urological interventions was 71.58 ±38.17 min., whereby hypospadias repairs accounted for the longest operative time. All inguinal skin closures in orchidopexy (N=40) were performed by the continuous-intracutaneous suture technique. Scrotal skin was closed by using an interrupted-transcutaneous suture technique. Hypospadias

repairs and circumcisions were performed by using the interrupted-transcutaneous suture technique. Monosyn® Quick United States Pharmacopoeia size (USP) 5/0 attached to a DSMP 11 needle was the preferred suture for skin closure in orchidopexy, while in hypospadias repairs USP 6/0 with DGMP 11 needle was the most frequently used material. The median number of threads applied for tissue adaptation was 1 for all urological interventions. The number of threads per indication is shown in Table 2.

Table 2. Intrasurgical data.

Parameter	Number (N)	Median (Range)	Mean (SD)
Reason for surgery	40 (75.47%)		
Orchidopexy			
Hypospadias	10 (18.87%)		
Buried penis	1 (1.89%)		
Circumcision + orchidopexy	1 (1.89%)		
Circumcision + penoscrotal transposition	1 (1.89%)		
Duration of surgery (min)			
All	53	63.00 (18.00 – 227.00)	71.58 (38.17)
Orchidopexy	40	60.00 (18.00 – 180.00)	60.88 (29.41)
Hypospadias	10	101.00 (40.00 – 227.00)	101 (48.70)
Buried penis	1	72.00 (72.00 – 72.00)	
Circumcision + orchidopexy	1	87.00 (87.00 – 87.00)	
Circumcision+ penoscrotal transposition	1	90.00 (90.00 – 90.00)	
Suture technique			
Continuous/intracutaneous	40		
Interrupted/transcutaneous	53		
Type of thread			
USP 4/0 with DSMP19	1		
USP 5/0 with DSMP 11	40		
USP 6/0 with DGMP 11	11		
Combination of USP 5/0 and USP 6/0	1		
Number of threads			
All		1.0 (1-5)	
Orchidopexy		1.0 (1-2)	
Hypospadias		2.5 (1-5)	

3.4. Handling of the Suture Material

All handling categories were predominately judged with 4-5 points from the 5-point Likert scale, indicating that the suture material was very good to excellent to handle, Figure 2.

3.5. Hospital Stay

For post-surgical length of hospital stay, an average of 1.32 ±1.27 days was reported, ranging from 0 to 6 days after surgery. Children who underwent an orchidopexy left the

clinic either on the day of surgery or one day postoperatively. After hypospadias repair, paediatric patients usually stayed in the hospital for 2 days.

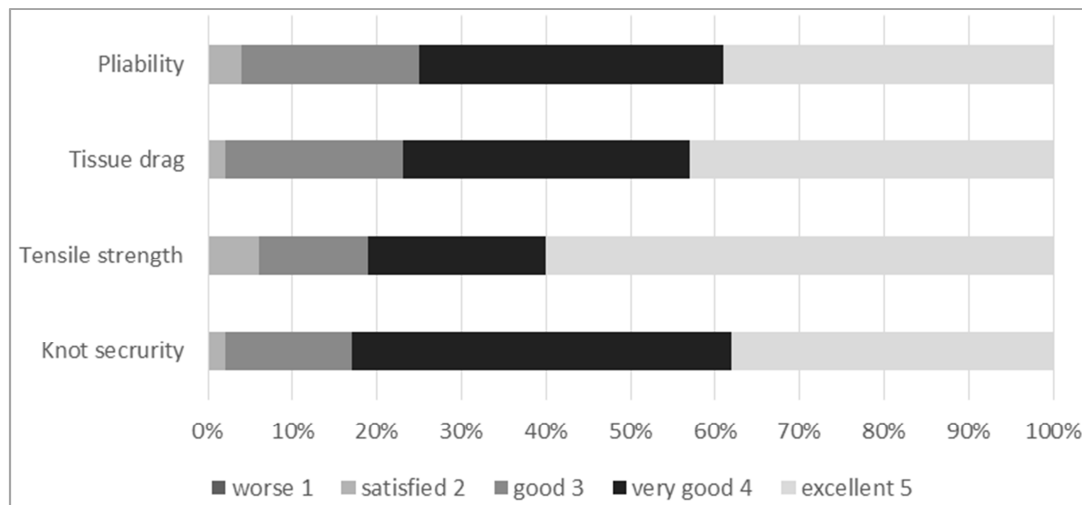


Figure 2. Handling categories of the suture material.

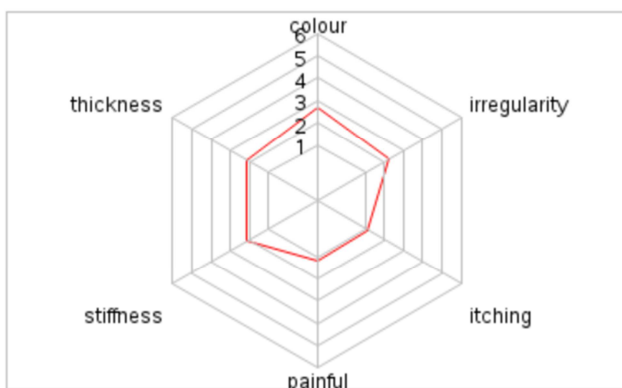


Figure 3. Patient assessment of scar quality: POSAS patient component.

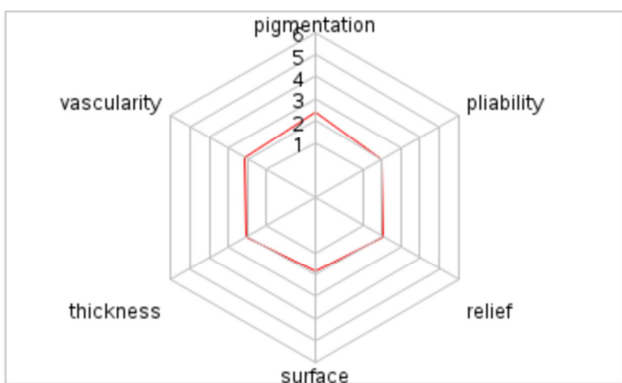


Figure 4. Observer assessment of scar quality: POSAS observer component.

3.6. Scar Assessment Using the POSAS

Scar quality assessment was performed by surgeons as well as the patients/parents 3 months postoperatively. The patient component of the POSAS was mainly rated by the parents due to the children's age. The POSAS results are shown in Figures 3 and 4. The total POSAS score of the

patient dimensions was 11.56 ± 5.84 and 12.52 ± 6.51 for the observer dimensions. The overall appearance of the scar was judged by the parents/patients with 2.31 ± 1.54 [min. 1.00 – max. 8.00] and with 1.90 ± 1.07 [min. 1.00 – max. 7.00] by the surgeons. The outcome indicated that the wound healing was excellent in the observer's as well as in the patient's/parent's view. The patient's and observer's assessments were largely consistent.

3.7. Complications

We analysed the incidence of common complications following surgical skin closure. Neither wound dehiscence nor wound infection or delayed wound healing was observed. In addition, no urethrocutaneous fistula, meatal stenosis, urethral stricture, tissue reaction, bleeding, allergic reaction or inflammatory reaction was reported until 3 months postoperatively. All threads were left in situ due to their absorbable feature and the uncomplicated postoperative courses. During knot-tying, two threads ruptured and were recorded as suture-related device defects.

4. Discussion

To our knowledge, this is the first prospective study analysing the clinical performance of a quick-absorbable, monofilament suture (Monosyn® Quick) for wound closure in various paediatric urological operative repairs. The rate of wound healing complications after interrupted intracutaneous or continuous intracutaneous suture application was 0%. Intra-surgical handling was rated as very good by the applying surgeons, while the aesthetic outcome 3 months after surgery using the POSAS assessment was rated as excellent by both observer and patient/parent.

Fast-absorbing, braided, multifilament sutures, such as Vicryl® Rapide (polyglactin 910), are widely used for severe surgical procedures and have been evaluated as a good

alternative to non-absorbable sutures or slow-absorbable sutures in several surgical indications in the paediatric and young adult population [18-21].

In urologic procedures, absorbable sutures have been reviewed in several studies and are considered an adequate choice of treatment. Giri et al. retrospectively reviewed medical records of patients who underwent laparoscopic pyeloplasty from January 2013 to May 2014. A total of 37 patients received the surgical procedure using a delayed-absorbable suture (4-0 Vicryl®) applied in a continuous suture technique. Patients were followed up for 3 months. Postoperatively, no urinary leak was detected; urinary tract infections were found in 2 patients [22]. Results of this study showed that delayed-absorbable sutures such as Vicryl® seem to be adequate in paediatric and young patients, being associated with a small proportion of patients suffering of postoperative complications.

Whilst the use of absorbable sutures for hypospadias repair has been universally accepted, there is no general agreement on the suture technique (continuous or interrupted). The most common complication after hypospadias is the occurrence of an urethrocutaneous fistula. Depending on the suture technique the reported fistula rate ranges from 9 to 23% [2, 23]. To analyse the effect of the suture technique on the clinical outcome of the hypospadias repair, Gypta et al. performed a randomised controlled trial for primary anterior hypospadias repair comparing an interrupted subcuticular suture versus a continuous subcuticular suture in 100 boys (12 to 66 months old) [9]. The clinical outcome measures included assessment of postoperative complications and aesthetic appearance. Patients were examined monthly for the first 6 months and then every 6 months with a maximal duration of 3 years. Assessors were blinded to the applied suture technique. There was no difference regarding complications. The most common complication was the occurrence of an urethrocutaneous fistula, with 12% in the interrupted and 14% in the continuous suture group. A partial glans dehiscence was seen in one patient in each group. In addition, one wound infection, one meatal stenosis and one urethral stricture occurred in each treatment group. The total complication rate was 20% in the interrupted group and 22% in the continuous group. Satisfaction with the aesthetic appearance was judged in all patients with a score of 8-9. The authors concluded that the type of suture technique has no influence on the clinical outcome following hypospadias repairs. The choice of the suture technique mainly depends on the preference of the surgeon.

Similar results were found by Sarhan et al. [6]. They also investigated the continuous suture technique versus the interrupted suture technique for hypospadias repair in 80 boys randomly distributed to both suture groups. Complications developed in 11 patients and consisted of 8 fistulas, 2 dehiscences and three meatal stenoses. The complication rate was independent of the used suture technique.

To investigate the effect of the suture material on the clinical outcome after hypospadias interventions, several prospective and retrospective studies have been conducted in

the past.

A retrospective analysis of a paediatric population consisting of 80 patients with hypospadias that underwent tubularised incised plate (TIP) urethroplasty between November 2007 and March 2012 assessed factors that might influence the safety outcome. The neourethra was tubularized over a tube with either absorbable Maxon® suture in 28 patients or with 6/0 Vicryl® suture in 58 patients. All surgeries were performed by one surgeon, follow-up was at least one year and the presence of complications requiring reoperation and general appearance was recorded. Reoperation was needed in 19 boys (23.75%) due to urethrocutaneous fistula (15%), a complete disruption of the repair (3.75%) and meatal stenosis (4%). The observed complication rate was 25% in the Maxon® group and 21% in the Vicryl® group. The authors concluded that the type of hypospadias influences the complication rate and that a better outcome depends on the experience of the surgeon [8].

Mohamed et al. performed a prospective study which evaluated 55 patients who received polyglactin (PGA) and 50 patients who obtained polydioxanone (PDO) based suture material for hypospadias repair. The aim of the study was to analyse the complication rate, especially the rate of urethrocutaneous fistulas. Total complication rate including different types of adverse events 6 months after surgery was 34% in the PGA group and 10.9% in the PDO group. The most frequent complication in the study was urethrocutaneous fistula development (18.1%), with 13.3% urethrocutaneous fistula in the PGA group compared to 4.8% in the PDO group. Another significant complication was meatal stenosis (10.5%), which occurred in 9 PGA patients (8.6%) and 2 PDO patients (3.6%). It was summarised that PDO leads to a better outcome, because of its lower rate of urethrocutaneous fistulas. Factors that could influence the development of urethrocutaneous fistula were identified as type of hypospadias, type of repair, stage of repair, type of suture material and meatal stenosis [10].

A cohort study of Shirazi et al. comprised 583 children aged 1-7 years who had undergone an operative repair of hypospadias. The retrospective analysis compared the post-urethroplasty complication rate between a Vicryl® and a polydioxanone (PDO) suture group. A total of 60 patients (10.3%) developed a complication consisting of urethrocutaneous fistulas (N=39, 6.7%), meatal stenoses (N=10, 1.7%), urethral strictures (N=7, 1.2%) and glans dehiscence (N=4, 0.7%). The comparison revealed that the complication rate was higher with Vicryl® than with PDO (15.1% vs. 5.3%, respectively), [11]. Authors suggested the use of long-term absorbable PDO sutures due to their lower complication rate.

In our cohort group, neither urethrocutaneous fistulas nor meatal stenoses or urethral strictures or glans dehiscences were observed during a 3-month follow-up. Both continuous intracutaneous and interrupted transcutaneous suture techniques were used and both led to an excellent clinical outcome without complications. We used a quick-absorbable monofilament suture (Monosyn® Quick) for tissue adaptation.

The tensile strength and total absorption time of Monosyn® Quick ranged between that of fast-absorbable-braided PGA and standard braided PGA suture. Monosyn® Quick loses its tensile strength much quicker and is completely absorbed much faster than PDO sutures.

Limitations of our study are the short-follow-up time of 3 months after surgery, which may not allow to detect mid- and long-term complications regarding scar tissue remodelling. Another limitation is the small sample size and the observational design without a control group.

In our prospective consecutive cohort study we included a paediatric population which underwent common urologic surgeries frequently performed in that age group. Our results indicate that the tested quick-absorbable monofilament suture (Monosyn® Quick) may be a valuable alternative to the existing slower absorbable monofilament sutures, especially on the basis of a low complication rate and very good POSAS rating in our small cohort.

5. Conclusion

Our findings indicate that Monosyn® Quick is safe and effective for skin closures in different paediatric urological interventions. The suture material offers a very good intraoperative handling and leads to an excellent aesthetic outcome. Therefore, Monosyn® Quick is a good alternative to other suture materials used for paediatric urological surgical procedures such as fast-absorbable or standard absorbable braided PGA sutures or long-term absorbable monofilament PDO sutures.

Funding

This study was sponsored and funded by B. Braun Surgical S. A., Rubi, Spain. The Medical Scientific Affairs Department of Aesculap AG was responsible for project management, monitoring, data management, statistics, and study registration.

Author's Contribution

PB designed the study and wrote the manuscript together with SG. Both authors reviewed and approved the final manuscript.

Conflict of Interest

SG declares no competing interest. PB is an employee of Aesculap AG.

Acknowledgments

The authors would like to thank Viktor Breul for statistical analysis. We deliver our special acknowledgement to the medical staff of the University Hospital Frankfurt, Department of Paediatric Surgery and to all patients and their families who participated in our study.

References

- [1] Adams, J. & Bracka, A. (2016). Reconstructive surgery for hypospadias: A systematic review of long-term patient satisfaction with cosmetic outcomes. *Indian J Urol*, 32 (2), 93-102. doi: 10.4103/0970-1591.179178.
- [2] Matthew, A., & Elterman, D. (2014). Men's mental health: Connection to urologic health. *Can Urol Assoc J*, 8 (7-8 Suppl 5), S153-155. doi: 10.5489/cuaj.2312.
- [3] Gfroerer, S., Baumann, P., Schwalbach, A. K., & Smirnov, A. (2019). Prospective international multicenter observational study of Novosyn (R) Quick for skin closures in adults and children (SKINNOQ). *BMC Surg*, 19 (1), 47. doi: 10.1186/s12893-019-0506-8.
- [4] European Association of Urology. (2022). EAU Guidelines. Edn. presented at the EAU Annual Congress Amsterdam. Retrieved from <https://d56bochluxqnz.cloudfront.net/documents/full-guidelines/EAU-Guidelines-on-Paediatric-Urology-2022.pdf>
- [5] Sarikaya, K., Senocak, C., Sadioglu, F. E., Ciftci, M., Yordam, M., Bozkurt, O. F., & Ibis, M. A. (2022). Is there any advantage in the use of absorbable sutures in congenital penile curvature surgery performed in childhood? *Rev Int Androl*, 20 (3), 158-162. doi: 10.1016/j.androl.2020.12.005.
- [6] Sarhan O, Saad M, Helmy T, Hafez A (2009). Effect of suturing technique and urethral plate characteristics on complication rate following hypospadias repair: a prospective randomized study. *J Urol*; 182 (2): 682-5; discussion 685-6. doi: 10.1016/j.juro.2009.04.034.
- [7] Snodgrass WT. Hypospadias In: Wein AJ, Kavoussi LR, Novick AW, Partin AW, Peters CA, editors. *Campbell-Walsh urology*. 10th ed. Philadelphia: Elsevier Saunders; 2012; 3502-36.
- [8] Viseshsindh, W. (2014). Factors affecting results of hypospadias repair: single technique and surgeon. *J Med Assoc Thai*, 97 (7), 694-698.
- [9] Gupta A, Gupta R, Srivastav P, Gupta A (2017). Comparison of interrupted- and continuous-suture urethroplasty in tubularised incised-plate hypospadias repair: A prospective study. *Arab J Urol*; 15 (4): 312-318. doi: 10.1016/j.aju.2017.10.004.
- [10] Mohamed Ali Alaraby, S. O., Abdeljaleel, I. A., Hamza, A. A., & Elawad Elhassan, A. E. (2021). A comparative study of polydioxanone (PDS) and polyglactin (Vicryl) in hypospadias repair. *Afr J Paediatr Surg*, 18 (1), 53-57. doi: 10.4103/ajps. AJPS_90_20.
- [11] Shirazi, M., Haghpanah, A., Dehghani, A., Haghpanah, S., Ghahartars, M., & Rahmanian, M. (2022). Comparison of post-urethroplasty complication rates in pediatric cases with hypospadias using Vicryl or polydioxanone sutures. *Asian J Urol*, 9 (2), 165-169. doi: 10.1016/j.ajur.2021.08.010.
- [12] Guarino N, Vallasciani SA, Marrocco G. A new suture material for hypospadias surgery: a comparative study. *J Urol*. 2009 Mar; 181(3): 1318-22; discussion 1322-3. doi: 10.1016/j.juro.2008.10.056. Epub 2009 Jan 20. PMID: 19157423.
- [13] Ulman I, Erikçi V, Avanoğlu A, Gökdemir A. The effect of suturing technique and material on complication rate following hypospadias repair. *Eur J Pediatr Surg*. 1997 Jun; 7(3): 156-7. doi: 10.1055/s-2008-1071079. PMID: 9241502.

- [14] Shirazi M, Noorafshan A, Serhan A. Effects of different suture materials used for the repair of hypospadias: a stereological study in a rat model. *Urol Int.* 2012; 89(4): 395-401. doi: 10.1159/000343423. Epub 2012 Oct 26. PMID: 23108502.
- [15] Yassin, Tamer; Bahaaeldin, Khaled Husein; Husein, Ayman^a; El Minawi, Hisham. Assessment and management of urethrocutaneous fistula developing after hypospadias repair. *Annals of Pediatric Surgery* 7(2): p 88-93, April 2011. | DOI: 10.1097/01.XPS.0000397066.98404.82.
- [16] Matthew, G. & Agha, R. STROCCS Group (2021). STROCCS 21: Strengthening the reporting of cohort, cross-sectional and case-control studies in surgery. *Int J. Surg.* 96: 106165. doi: 10.1016/j.ijsu.2021.106165.
- [17] Draaijers, L. J., Tempelman, F. R., Botman, Y. A., Tuinebreijer, W. E., Middelkoop, E., Kreis, R. W., & van Zuijlen, P. P. (2004). The patient and observer scar assessment scale: a reliable and feasible tool for scar evaluation. *Plast Reconstr Surg*, 113 (7), 1960-1965; discussion 1966-1967. doi: 10.1097/01.prs.0000122207.28773.56.
- [18] Al-Qattan, M. M. (2005). Vicryl Rapide versus Vicryl suture in skin closure of the hand in children: a randomized prospective study. *J Hand Surg Br*, 30 (1), 90-91. doi: 10.1016/j.jhsb.2004.08.005.
- [19] Matsumine, H., & Takeuchi, M. (2013). Usefulness of Irradiated Polyglactin 910 (Vicryl Rapide) for Skin Suturing during Surgery for Lateral Ray Polydactyly of the Toes in Children. *Plast Reconstr Surg Glob Open*, 1 (6), e42. doi: 10.1097/GOX.0b013e3182a85b13.
- [20] Sidebottom, A. J., Grogan, J., May, P., & Richardson, D. (2003). Prospective comparison of methods of closure of the coronal flap after craniofacial surgery in children. *Br J Oral Maxillofac Surg*, 41 (5), 309-311. doi: 10.1016/s0266-4356(03)00143-8.
- [21] Tejani, C., Sivitz, A. B., Rosen, M. D., Nakanishi, A. K., Flood, R. G., Clott, M. A. & Luck, R. P. (2014). A comparison of cosmetic outcomes of lacerations on the extremities and trunk using absorbable versus nonabsorbable sutures. *Acad Emerg Med*, 21 (6), 637-643. doi: 10.1111/acem.12387.
- [22] Giri, V., Yadav, S. S., Tomar, V., Jha, A. K., & Garg, A. (2019). Retrospective comparison of outcomes of laparoscopic pyeloplasty using barbed suture versus nonbarbed suture: A single-center experience. *Urol Ann*, 11 (4), 410-413. doi: 10.4103/UA.UA_123_15.
- [23] El-Sherbiny MT, Hafez AT, Dawaba MS, Shorrab AA, Bazeed MA. (2004). Comprehensive analysis of tubularized incised-plate urethroplasty in primary and re-operative hypospadias. *BJU Int.*; 93 (7): 1057-61. doi: 10.1111/j.1464-410X.2004.04781.